

# Case Report: Treatment With Tocilizumab in a Patient With COVID-19



Hamideh Abbaspour Kasgari<sup>1</sup> , Hamidreza Samaee<sup>1</sup> , Shahriar Alian Samakkhah<sup>2</sup> , Parisa Moradimajd<sup>3\*</sup>

1. Department of Clinical Pharmacy, Faculty of Pharmacy, Mazandaran University of Medical Sciences, Sari, Iran.
2. Department of Infectious Diseases, Faculty of Medicine, Mazandaran University of Medical Sciences, Sari, Iran.
3. Department of Anesthesia, Faculty of Allied Medical Sciences, Iran University of Medical Sciences, Tehran, Iran.

\* Corresponding Author:

Parisa Moradimajd, PhD.

Address: Department of Anesthesia, Faculty of Allied Medicine, Iran University of Medical Sciences, Tehran, Iran.

Phone: +98 (912) 0885842

E-mail: moradimajd.p@iums.ac.ir



Copyright© 2020, The Authors.

## Article info:

Received: 06 June 2020

Accepted: 28 June 2020

## Keywords:

Coronavirus, Tocilizumab, Pandemic, COVID-19

## ABSTRACT

In late December 2019, a global outbreak (pandemic) of the coronavirus was reported, which WHO named 2019-nCoV. The virus is now spreading rapidly and has affected many countries, including Iran. There is no definitive and effective treatment for this virus yet. This report aimed to define the effect of Tocilizumab in patient with COVID-19. This case report is about a 52-year-old man with COVID-19 that has been treated with tocilizumab. The reported patient had an acceptable improvement in oxygen saturation but no significant change in lung CT scan. After 3 days treatment patient with Tocilizumab, extensive bilateral lungs involvement still exist but SPO<sub>2</sub> level improvement up to 90%. According to the results, this drug had a positive impact on oxygen saturation. However, we cannot be certain whether this drug positively affected the patient's coronavirus disease.

## 1. Introduction

The World Health Organization named SARS-CoV2 virus as COVID-19. It was first appeared in December 2019 in China and spread in neighboring countries like South Korea and Japan and then all over the world very fast [1].

Coronaviruses are important pathogens in humans and animals [2]. There are 76288 infected cases and 2345 deaths from COVID-19 reported until February 21, 2020, in China [3]. Now the virus is spreading rapidly, and it has involved many countries, including Iran [4].

According to reported deaths and the affected patients until now, WHO was forced to declare a public health emergency in late January 2020 [5]. Researchers try to discover effective treatments for the emerging virus. About 30 drugs have been introduced to treat this disease so far, including herbal products and chemical drugs with different mechanisms [6]. Some antiviral drugs recommended by Chinese researchers include lopinavir, ritonavir, oseltamivir, and ganciclovir. Short-term treatment with corticosteroids such as methylprednisolone reduces inflammation of the lung tissue, and some antibiotics are recommended to prevent bacterial infections associated with viral infections, too [7]. Drugs used for respiratory infections caused by COVID-19 are

**Citation** Abbaspour Kasgari H, Samaee HR, Alian Samakkhah S, Moradimajd P. Treatment With Tocilizumab in a Patient With COVID-19. Pharmaceutical and Biomedical Research. 2020; 6 (Special Issue on COVID-19):111-116. [http://dx.doi.org/10.18502/pbr.v6i\(S2\).5662](http://dx.doi.org/10.18502/pbr.v6i(S2).5662)

[http://dx.doi.org/10.18502/pbr.v6i\(S2\).5662](http://dx.doi.org/10.18502/pbr.v6i(S2).5662)

classified into three categories: drugs that strengthen the immune system (interferon, globulin), chloroquine phosphate, and antiviral drugs (oseltamivir) [8].

One of the drugs discussed for the treatment of these patients is tocilizumab. It is an interleukin-6 (IL-6) receptor antagonist and reduces the level of inflammatory markers, including RF, ESR, and amyloid A, to the normal range [9]. IL-6 is produced in response to tissue injuries and various types of infections. Also, it contributes to host defense through activation of immune responses and stimulation of acute phase reactions. IL-6 has great importance in the pathogenesis of various inflammatory diseases, including infectious inflammations, and for this reason, tocilizumab, an anti-IL-6 receptor antibody, has been developed and recommended for treating patients with COVID-19 [10].

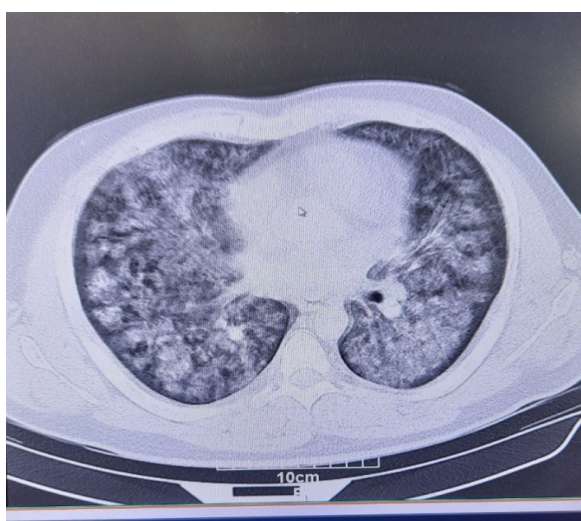We report a 52-year-old man with a definite COVID-19 infection who died despite receiving tocilizumab.

## 2. Case Presentation

A 52-year-old man (168 cm height, 70 kg weight) with symptoms of dry cough, dyspnea, fever, and myalgia was referred to the emergency department of Razi Hospital in Ghaemshahr City, Iran, on March 5, 2020. The patient's symptoms started one week before the visit. At the time of admission, the patient had a fever ( $T=38^{\circ}\text{C}$ ), oxygen saturation of 74% with a pulse oximeter, and other symptoms were normal. Based on the taken history, the patient had direct contact with an infected person. The patient's

medical history included taking 500 mg metformin daily. He didn't use any antibiotics. Due to the suspected symptoms of COVID-19 and the patient's direct contact with an infected person, a CT scan of the patient's lung, sampling of the patient's nose and throat to perform RT-PCR test, and other routine tests were requested. The patient's RT-PCR was positive, and he was admitted with a definite diagnosis of moderate-intensity COVID-19. CT scan of the patient's lungs showed extensive bilateral involvement (Figure 1). The results of the patient's initial tests given before tocilizumab administration were presented in Table 1 and Table 2. Lymphopenia is evident in the patient's test results, and other lab tests were normal.

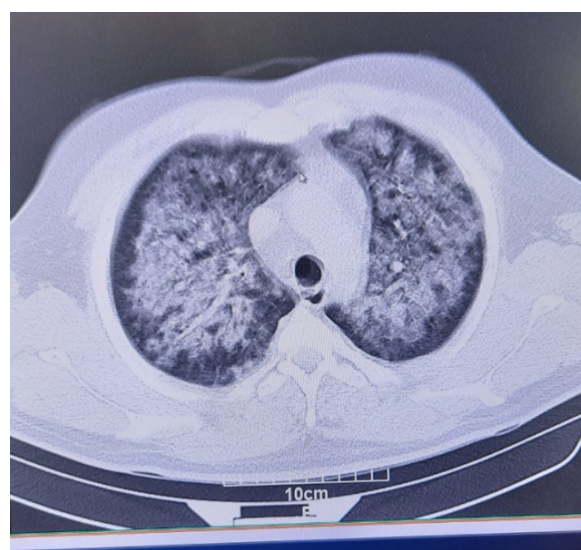
After admission, a 4-drug regimen was administered to the patient. The 4-drug regimen included hydroxychloroquine 400 mg daily, ribavirin 600 mg BD, Kaletra (lopinavir 200/ritonavir 50) 2 tablets BD, and oseltamivir 75 mg BD. Empiric antibiotic treatment (vancomycin 1 g daily and meropenem 1 g TDS) was also started for the patient. Due to severe nausea and vomiting induced with drugs, such as Kaletra, promethazine 25 mg daily was administered for the patient by the clinical pharmacy service. Despite receiving a 4-drug regimen, the patient's dyspnea and his oxygen saturation worsened on the third day of admission, and he was admitted to ICU. The patient underwent mechanical ventilation on March 8, 2020. According to the general condition of the patient, the interleukin-6 (IL-6) level was requested by the clinical pharmacy service, and due to the high level of IL-6, after the necessary evaluations, tocilizumab was



**PBR**

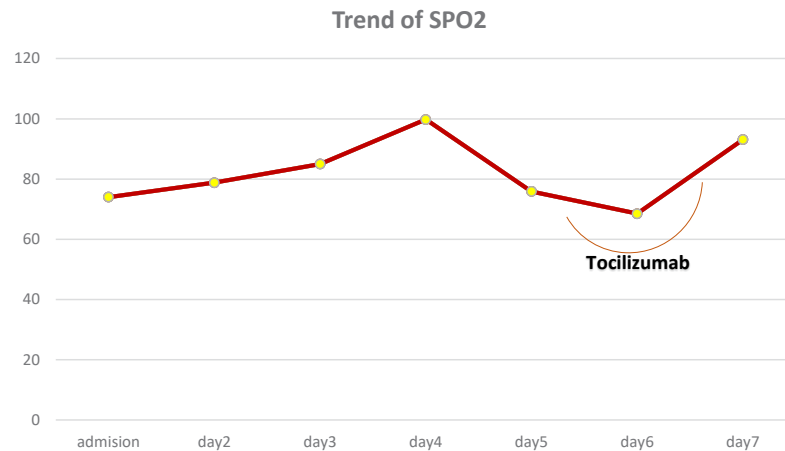
**Figure 1.** The patient's CT scan with COVID-19 pneumonia before tocilizumab administration

There is evidence of bilateral interstitial thickening's consistent with ARDS



**PBR**

**Figure 2.** The patient's CT scan after tocilizumab administration. There is evidence of bilateral interstitial thickening's consistent with ARDS



**Figure 3.** SPO<sub>2</sub> changes after tocilizumab administration

**PBR**

administered for the patient. Because of the emergency condition of the patient, a PPD test was not used to evaluate the start of tocilizumab. Each vial of tocilizumab was diluted in 100 mL normal saline and infused intra-

venously in 60 min with a dose of 8 mg/kg. The patient was treated with tocilizumab for 3 consecutive days. On the third day, the CT scan of the patient’s lungs still showed extensive bilateral involvement (Figure 2). Also,

**Table 1.** The patient’s lab data

Lab Test	Result
Lymphocyte	0.2
Neutrophil	82
Monocyte	5
WBC	7.4
PLT	179000
LDH	840
CPKMB	5
Troponin	89.6
FBS	194
Na	157
K	4.6
BUN	51
Cr	0.8
HCT	40%
Hb	13
Pt	15
INR	1.4
Amilaz	20

**PBR**

**Table 2.** Lab data before tocilizumab administration

Parameter	Result
Infection	Negative
PPD	Negative
FBS	194
(ALT, AST)LFT	ALT= 20 , AST=40
Lipid Profile (Cholesterol, HDL, LDL, TG)	Normal



the trend of changes in SPO<sub>2</sub> is shown in Figure 3. Unfortunately, the patient died on March 11, 2020.

### 3. Conclusion

COVID-19 is spreading rapidly, and so far, no definitive treatment has been reported for it. Recently, tocilizumab has been considered one of the treatments of drugs for patients with COVID-19, and researchers are investigating and conducting clinical trials on this drug [1, 9]. Tocilizumab (also sold with trade names “Atlizumab” and “Actemra”) is a humanized monoclonal antibody against the IL-6 receptor. IL-6 acts as both a pro-inflammatory cytokine and an anti-inflammatory myokine [9]. A decade ago, FDA approved tocilizumab for the treatment of rheumatoid arthritis and cytokine inflammations in cancer patients undergoing cell therapy [10]. Cytokine storm is one reason for the organ failure and severe deterioration of patients with COVID-19 infection. Virus entry into the lung cells releases inflammatory factors, such as IL-6, causing edema, lung involvement, and decreased blood oxygen [11, 12]. Therefore drugs used in the past for the treatment of Cytokine Release Syndrome (CRS) were considered as candidates for COVID-19 treatment, and the use of these drugs, such as tocilizumab by affecting IL-6, in patients with severe conditions has been suggested [10]. In our case, after tocilizumab administration, blood oxygen saturation was improved, but no change in CT scan.

It should be noted that tocilizumab is not an antiviral drug, and it can be useful in patients with inflammation and destruction of the lung caused by COVID-19. Tocilizumab can be used in a specific age range and probably useful in patients with high blood IL-6 levels.

Clinical data of this patient show the positive effect of tocilizumab on SPO<sub>2</sub>, and perhaps this drug can be an effective and hopeful treatment for improving inflammation of the lung. But it is not possible to rely certainly on

this therapeutic response as our patient died after receiving 3 doses of tocilizumab. In this regard, further studies and more extensive clinical data are needed to prove the efficacy of tocilizumab.

### Ethical Considerations

#### Compliance with ethical guidelines

All ethical principles are considered in this article. The participants were informed of the purpose of the research and its implementation stages. They were also assured about the confidentiality of their information and were free to leave the study whenever they wished, and if desired, the research results would be available to them.

#### Funding

This research did not receive any grant from funding agencies in the public, commercial, or non-profit sectors.

#### Authors' contributions

Writing – original draft: Hamideh Abbaspour Kasgari and Parisa Moradimajd; Data collection: Hamidreza Sammaee and Shahriar Alian Samakkhah;

#### Conflict of interest

The authors declared no conflicts of interest

### References

- [1] Lu H, Stratton CW, Tang YW. Outbreak of pneumonia of unknown etiology in Wuhan China: The mystery and the miracle. *Lancet Infect Dis.* 2020; 20(4):397-8. [DOI:10.1016/S1473-3099(20)30110-9]

- [2] Li Q, Guan X, Wu P, Wang X, Zhou L, Tong Y, et al. Early transmission dynamics in Wuhan, China, of novel coronavirus-infected pneumonia. *N Engl J Med.* 2020; 382(13):1199-207. [DOI:10.1056/NEJMoa2001316] [PMID] [PMCID]
- [3] World Health Organization (WHO). WHO informal consultation on a framework for scabies control, meeting report. World Health Organization Regional Office for the Western Pacific, Manila, Philippines, 19-21 February 2019. <https://www.who.int/publications/i/item/9789240008069>
- [4] Zumla A, Hui DS, Azhar EI, Memish ZA, Maeurer M. Reducing mortality from 2019-nCoV: Host-directed therapies should be an option. *Lancet* 2020; 395(10224):e35-6. [DOI:10.1016/S0140-6736(20)30305-6]
- [5] Chen N, Zhou M, Dong X, Qu J, Gong F, Han Y, et al. Epidemiological and clinical characteristics of 99 cases of 2019 novel coronavirus pneumonia in Wuhan, China: A descriptive study. *Lancet.* 2020; 395:507-13. [DOI:10.1016/S0140-6736(20)30211-7]
- [6] Huang C, Wang Y, Li X, Ren L, Zhao J, Hu Y, et al. Clinical features of patients infected with 2019 novel coronavirus in Wuhan, China. *Lancet.* 2020; 395:497-506. [DOI:10.1016/S0140-6736(20)30183-5]
- [7] She J, Jiang J, Ye L, Hu L, Bai C, Song Y. 2019 novel coronavirus of pneumonia in Wuhan, China: Emerging attack and management strategies. *Clin Transl Med.* 2020; 9(1):1-7. [DOI:10.1186/s40169-020-00271-z] [PMID] [PMCID]
- [8] Oldfield V, Dhillon S, Plosker G L. Tocilizumab: A review of its use in the management of rheumatoid arthritis. *Drugs.* 2009; 69:609-32. [DOI:10.2165/00003495-200969050-00007] [PMID]
- [9] Samaee H, Mohsenzadegan M, Ala S, Maroufi SS, Moradimajd P. Tocilizumab for treatment patients with COVID-19: Recommended medication for novel disease. *Int Immunopharmacol.* 2020; 89(Pt A):107018. [DOI:10.1016/j.intimp.2020.107018] [PMID] [PMCID]
- [10] Abbaspour Kasgari H, Babamahmoodi F, Davoudi Badabi AR, Abbaskhani Davanloo A, Moradimajd P, Samaee H. Combination Therapy with Remdisivir and Tocilizumab for COVID-19: Lessons for Futures Studies. *Arch Clin Infect Dis.* 2020; 15(4):e103537. [DOI:10.5812/archcid.103537]
- [11] Hu B, Zeng LP, Yang XL, Ge XY, Zhang W, Li B, et al. Discovery of a rich gene pool of bat SARS-related coronaviruses provides new insights into the origin of SARS coronavirus. *PLoS Pathog* 2017; 13(11):e1006698. [DOI:10.1371/journal.ppat.1006698] [PMID] [PMCID]
- [12] Yang X, Yu Y, Xu J, Shu H, Liu H, Wu Y, et al. Clinical course and outcomes of critically ill patients with SARS-CoV-2 pneumonia in Wuhan, China: A single-centered, retrospective, observational study. *Lancet Respir Med.* 2020; 8(5):475-81. [DOI:10.1016/S2213-2600(20)30079-5]

This Page Intentionally Left Blank