

Original Article:

The Effects of Vitamin C on the Quality of Semen, Testicular Tissue, and Apoptosis in Mice Exposed to Sodium Arsenite



Ebrahim Cheraghi¹ , Hamid Piroozmanesh², Malek Soleimani Mehranjani^{2*}

1. Department of Biology, Faculty of Sciences, University of Qom, Qom, Iran.

2. Department of Biology, Faculty of Sciences, University of Arak, Arak, Iran.

* Corresponding Author:

Malek Soleimani Mehranjani, PhD.

Address: Department of Biology, Faculty of Sciences, Arak University, Arak, Iran.

Phone: +98 (918) 1617098

E-mail: m-soleimani@araku.ac.ir



Copyright© 2020, The Authors.

Article info:

Received: 20 May 2021

Accepted: 13 Sep 2021

Keywords:

Sodium arsenite, Vitamin C, Apoptosis, Testis, Mice

ABSTRACT

Background: Arsenic is a heavy metal that causes malformation. It affects the reproductive system of men by induction of oxidative stress.

Objectives: This study investigated the effect of Vitamin C (Vit C), as a potent antioxidant, on sperm quality and testicular tissue in mice that received sodium arsenite.

Methods: A total of 28 adult male NMRI mice were divided into four groups: control, sodium arsenite (7 mg/kg/d), Vitamin C (Vit C; 150 mg/kg/d), and sodium arsenite+Vit C (with previous doses). Gavage treatments were administered for 35 days. At the end of the treatments, the right testis was used for histopathological observations and apoptosis assessment, and the left testis to evaluate sperm parameters.

Results: Sperm parameters such as count, motility, viability, morphology, tail length, Daily Sperm Production (DSP), the diameter of seminiferous tubules, the height of the germinal epithelium, and the number of germ cells and Sertoli cells were significantly decreased in the sodium arsenite group compared to the control group ($P < 0.05$). Malondialdehyde levels were significantly increased, and serum testosterone levels were significantly reduced in the sodium arsenite group. The mentioned parameters were compensated for in the sodium arsenite+Vit C group compared to the sodium arsenite group ($P < 0.05$).

Conclusion: Vitamin C can decrease the undesired changes induced by sodium arsenite in the male reproductive system.

Introduction

A

rsenic is an environmental toxicant that is used in agricultural pesticides, insecticides, herbicides, rodenticides, food and wood preservatives, metallurgic applications, and glass production. Also, it is considered a catalyst in several manu-

facturing processes [1]. In many populations, drinking water is the key route of exposure to arsenic [2]. The exposure can cause both acute and chronic disorders in humans, including diabetes, gastrointestinal tract disorders, as well as degenerative, inflammatory, and neoplastic alterations in the respiratory, hematopoietic, cardiovascular, and nervous system [3].

Citation Cheraghi E, Piroozmanesh H, Soleimani Mehranjani M. Research Paper: The Effects of Vitamin C on the Quality of Semen, Testicular Tissue, and Apoptosis in Mice Exposed to Sodium Arsenite. Pharmaceutical and Biomedical Research. 2022; 8(1):13-22. <http://dx.doi.org/10.18502/pbr.v8i1.9382>

<http://dx.doi.org/10.18502/pbr.v8i1.9382>

Investigations have also shown that arsenite can accumulate in the testes, seminal vesicles, and prostate glands. This accumulation can disturb the male genital system. This disturbance is characterized by the low number of sperm, reduced sperm motility, increased abnormal spermatozoa, and impaired spermatogenesis [4]. Arsenic toxicity is accompanied by an increase in the formation of Reactive Oxygen Species (ROS), imbalance of cellular redox, and the occurrence of oxidative stress, which in turn alters the membrane structure and cellular integrity through lipid peroxidation, causing irreversible cell damages [5].

Vitamin C (Vit C) is essential for many biological functions and plays a crucial role in preventing oxidative damage through its antioxidant properties [6]. In addition, Vit C causes the hydroxylation of essential amino acids and many oxidase enzymes that are involved in the catabolism of pesticides, heavy metals, and steroids [6]. Vit C can also restore antioxidants such as vitamin E. Many studies have suggested that one of the most important activities of Vit C is to reproduce the tocopheroxyl radical [7, 8].

Studies have illustrated its ability to protect the testicular tissue, maintain the sperm's normal morphology and reduce oxidative DNA damage in humans [9], rabbits [10], and rats [6]. Since Vit C is crucial for preserving the integrity of testis, epididymis, and the accessory glands [11], this study aimed to investigate the effect of sodium arsenite on mice testes and sperm parameters and the protective effect of Vit C in them.

Materials and Methods

Study design

In this experiment, 28 adult male NMRI mice (8-10 weeks old, 35-40 g weight) were purchased from Pasteur's Institute, Iran, kept under 12-h light/dark cycles at $24 \pm 20^\circ\text{C}$, and fed with standard commercial laboratory chew and water. The study was approved by the Animal Ethics Committee of the Qom University (IR.QOM.REC.1399.012), Qom City, Iran. Mice were divided into the following groups: 1) control (distilled water was administered), 2) sodium arsenite (7 mg/kg/d) [12], 3) vitamin C (Vit C, 150 mg/kg/d) [13], and 4) sodium arsenite and Vit C (at the mentioned doses). The treatments in all groups were consecutively done orally for 35 days [14]. Finally, they were weighed and anesthetized; then, their epididymides were dissected in the Ham's F10. The released spermatozoa were utilized to evaluate sperm characteristics. In addition, the right testis was used for histopathological observations.

Assessment of sperm parameters

Sperm motility and count

To analyze sperm motility, the caudal epididymis was cut, and the semen was placed on a pre-warmed slide. In short, 10 μL of sperm suspension was located on the chamber of semen analysis. Five microscopic fields were assessed in each sample, and sperm motility was assessed for at least 200 sperm of each animal. The average of 5-consecutive estimations was considered as the total motility grade. The percentage of sperm motility was evaluated by patterns of motion as follows: Non-Progressively Motile Sperm (NPMS), Progressively Motile Sperm (PMS), and Non-Motile Sperm (NMS). Similar to the total number of sperms, the left caudal epididymis was dissected and transferred into the culture medium and fixed with formaldehyde 2% fixative (1 mL of the semen sample and 9 mL of the formaldehyde 2% fixative). Then, 10 μL of the sample was located on Neubauer hemocytometer chamber. The total number of sperms was calculated, and values were reported as the count of sperm per mL [15].

Sperm morphology and viability

Eosin-Nigrosin staining was utilized to analyze the morphology and viability of sperm (eosin and nigrosin solutions 1% and 10%, both from Merck, Germany). Thin smear slides were observed under the light microscope at 100x magnification. One hundred sperm were observed to detect sperm abnormalities in each sample [16].

Daily Sperm Production (DSP) and sperm tail length

To determine the daily sperm production, frozen testicular tissue was thawed and homogenized by the homogenization method. In brief, the decapsulated testicular tissue was homogenized in the waring blender using 10-15 mL homogenizing fluid (150 mmol NaCl, 0.05% (v/v) Triton X-100). The number of homogenization-resistant spermatid nuclei in each suspension was ascertained by hemocytometer counts. To estimate the daily sperm production, data from the hemocytometer counts were divided into 3.43 days. The length of the sperm tail was calculated based on stereological techniques used to estimate length in 2-dimensional space. For each sample, 100-200 sperm were counted under optical microscopy with a magnification of 40x. In each microscopic field, the system used for the test consisted of 2 components that encountered the image on the screen. The first component was the unbiased counting frame (left and inferior borders of the frame). If the sperm head did not collide with the forbidden line, it would be counted. The second component

was a rectangle with an inward Merz grid. Merz grid is a curve consisting of 2 equal semicircles [17].

Stereological study

For the stereological assessment, the testes were carefully dissected and fixed in a modified Davidson's fluid. The testes were paraffin-embedded, and 20 μ m and 5 μ m sections were collected through a rotary microtome, stained by Heidenhain Azan, and examined by a light microscope [17].

Testicular and plasma Malondialdehyde (MDA) levels

The testicular and plasma concentrations of Malondialdehyde (MDA) were assessed following exposure of the testicular homogenate and plasma to thiobarbituric acid [18] and were reported in nmol/mL.

TUNEL method for analysis of apoptosis

The TUNEL method was used to assess the rate of apoptotic cells of the testicular cells. Apoptosis in testicular cells was evaluated using terminal deoxynucleotidyl Transferase dUTP Nick End Labeling (TUNEL) assay by the in-situ cell death detection kit (Roche, Mannheim, Germany) [19].

Plasma hormone assay

For hormonal evaluation, 1 mL of the blood sample was obtained from the heart of each mouse. Then, its plasma was isolated through centrifuging and stored at -20°C. Plasma concentrations of testosterone were measured using a kit (Testosterone ELISA kit, Cat No., EIA-1559, DRG International, Inc) with a sensitivity of 0.9 ng/dL.

Statistical analysis

The normality of continuous variables was proved by the Kolmogorov-Smirnov test. The obtained data were analyzed by 1-way Analysis of Variance (ANOVA) and Tukey's post hoc test. The means were considered significantly different when $P < 0.05$. All analyses were done by SPSS software, v. 20.0 for Windows (SPSS Inc., Chicago, IL, USA).

Results

Body and testis weight

The body weight and testis weight of each mouse were recorded after administering all interventions. The mean body weight did not significantly differ among the groups ($P > 0.05$) (Table 1). The testis weight was significantly decreased in mice receiving sodium arsenite ($P = 0.02$) compared to the control. Meanwhile, tes-

tis weight showed a significant increase in the sodium arsenite+Vit C group compared with the sodium arsenite group ($P = 0.04$), but not with the control group (Table 1).

Analysis of sperm parameters

Results showed a significant decrease ($P = 0.003$) in the epididymal sperm count in the sodium arsenite group compared with the control group. In contrast, the sodium arsenite+Vit C group showed a very significant increase ($P = 0.003$) in the sperm count compared with the sodium arsenite group (Table 1). The sperm motility (%) was significantly decreased in mice receiving sodium arsenite ($P = 0.02$) compared to the control. Meanwhile, sperm motility showed a significant increase ($P = 0.03$) in the sodium arsenite+Vit C group compared with the sodium arsenite group. The motility rate was significantly enhanced ($P = 0.01$) in the Vit C group compared to the control one (Table 1). A significant decline ($P = 0.01$) was found in the percentage of viable sperm in the sodium arsenite group compared to the control group.

At the same time, the parameter was significantly increased ($P = 0.04$) in the sodium arsenite+Vit C group compared to the sodium arsenite group (Table 1). Mice treated with Vit C showed a significant increase ($P = 0.03$) in sperm viability compared to the control group (Table 1). Although the proportion of abnormal sperms showed a considerable rise ($P = 0.003$) in the sodium arsenite group, it reduced significantly ($P = 0.02$) in the sodium arsenite+Vit C group than the control level as compared to the sodium arsenite group (Table 1).

Stereological calculations

Sperm's tail length, total volume of the testis, volume of the seminiferous tubules, and interstitial tissue

Compared to the control group, the mean sperm tail length was significantly decreased in the sodium arsenite group ($P = 0.01$). Meanwhile, in the sodium arsenite+Vit C group, the sperm tail length was significantly longer than that of the sodium arsenite group. Also, in the Vit C group, there was a significant increase in the mean sperm tail length compared to the control group ($P = 0.01$) (Table 2).

A significant reduction in the mean total volume of the testis, volume of the seminiferous tubules, and the interstitial tissue were seen in the sodium arsenite group compared to the control group ($P = 0.02$). In contrast, the sodium arsenite +Vit C group showed no significant reduction in the above parameters compared with the control group ($P > 0.05$) (Table 2) (Figure 1).

Table 1. Comparing body and testis weight, sperm count, motility, abnormalities, viability in different groups of mice after the experiment

Parameters	Control Group	Sodium Arsenite	Vit C	Sodium Arsenite+Vit C	P-Value
Body weight (g)	32.45±1.53 ^a	31.30±2.23 ^a	32.66±3.48 ^a	33.71±3.2 ^a	0.243
Testis weight (g)	128.0±3.9 ^a	117.0±9.34 ^b	134.3±6.5 ^a	127.3±3.2 ^a	0.01
Sperm count (x10 ⁶)	6.7±0.85 ^a	4.82±0.36 ^b	9.05±0.73 ^a	6.09±0.45 ^c	0.001
Sperm motility (%)	83.0±4.60 ^a	75.0±1.36 ^b	87.0±2.52 ^c	80.5±4.46 ^a	0.001
Sperm normal morphology (%)	98.33±1.83 ^a	84.33±3.57 ^b	91.83±2.48 ^c	91.33±1.2 ^a	0.01
Sperm viability (%)	84.83±2.63 ^a	63.66±2.73 ^b	86.1±1.34 ^a	80.66±2.16 ^a	0.001

PBR

Values are presented as Mean±SD. Means with the same superscript letter do not differ significantly from each other (ANOVA, Tukey's test, P>0.05).

The length, diameter, basement membrane thickness, and the germinal epithelium height of seminiferous tubules

The sodium arsenite group showed a significant decline in mean diameter and the height of the germinal epithelium of the seminiferous tubules compared to the control group (P=0.001). At the same time, the parameters

mentioned above did not significantly change in the sodium arsenite+VitC group compared to the control group (P>0.05) (Table 2). It was found that the mean diameter and the height of the germinal epithelium of the seminiferous tubules became significantly higher (P=0.01) in the Vit C group than in the other groups. Meanwhile, the length of the seminiferous tubules and the basement

Table 2. Comparison of stereological assessment of testis tissue in experimental groups after 35 days of treatment

Parameters	Control Group	Sodium Arsenite	Vit C	Sodium Arsenite+Vit C	P-Value
Sperm tail length (μm)	85.95±4.39 ^a	80.14±3.20 ^b	91.76±1.59 ^c	86.31±3.57 ^a	0.001
Total volume of testis (mm ³)	89.62±2.4 ^a	79.96±7.89 ^b	91.76±4.99 ^a	88.34±3.87 ^a	0.01
Seminiferous tubules (mm ³)	77.32±3.71 ^a	69.01±7.14 ^b	80.28±4.47 ^a	76.36±4.89 ^a	0.01
Interstitial tissue (mm ³)	11.6±1.26 ^a	10.66±1.43 ^b	11.47±1.46 ^a	11.83±1.01 ^a	0.01
Length of seminiferous tubules	1.83±0.13 ^a	1.83±0.21 ^a	1.94±0.29 ^a	1.89±0.29 ^a	0.543
Thickness of basement membrane	1.83±0.21 ^a	1.83±0.21 ^a	1.89±0.29 ^a	1.94±0.24 ^a	0.376
Diameter of seminiferous tubules	165.89±2.35 ^a	153.12±5.25 ^b	174.4±2.65 ^c	164.24±2.17 ^a	0.001
Height of germinal epithelium	54.34±2.82 ^a	35.51±4.3 ^b	60.57±5.30 ^c	53.96±1.91 ^a	0.001
Spermatogonia A (x10 ⁶)	6.5±0.13 ^a	5.17±0.73 ^b	7.05±0.44 ^a	6.30±0.61 ^a	0.01
Spermatocyte (x10 ⁶)	22.15±1.40 ^a	15.63±1.92 ^b	25.62±0.85 ^c	22.9±1.75 ^a	0.01
Spermatid (x10 ⁶)	41.37±3.37 ^a	29.77±4.2 ^b	46.44±1.27 ^c	30.83±5.47 ^a	0.001
Sertoli cells (x10 ⁶)	3.31±0.24 ^a	2.35±0.4 ^b	3.0±0.44 ^a	3.58±0.2 ^a	0.01
*DSP (x10 ⁶)	27.83±2.6 ^a	22.5±1.04 ^b	35.0±2.4 ^c	29.5±2.79 ^a	0.001

PBR

Total volume of testis, seminiferous tubules, interstitial tissue; seminiferous tubules length, thickness of basement membrane, diameter of seminiferous tubules, height of germinal epithelium, spermatogonia A, spermatocyte, spermatid, and the Daily Sperm Production (DSP) in different groups of mice after the experiment. Values are presented as Mean±SD. Means with the same superscript letter do not differ significantly from each other (ANOVA, Tukey's test, P>0.05). *DSP: Daily Sperm Production.

Table 3. Testicular tissue level of MDA, serum level of MDA and testosterone in different groups of mice after the experiment

Parameters	Mean±SD				P
	Control Group	Sodium Arsenite	Vit C	Sodium Arsenite+Vit C	
Testicular tissue level of MDA (ng/dL)	5.1±0.14 ^a	6.7±0.32 ^b	4.1±0.21 ^d	5.4±0.35 ^a	0.001
Serum level of MDA (ng/dL)	8.95±0.65 ^a	10.7±0.85 ^b	9.61±0.34 ^a	8.1±0.38 ^c	0.001
Testosterone (nmol/mL)	1.51±0.21 ^a	1.01±0.10 ^b	1.08±0.13 ^a	1.36±0.32 ^a	0.01

PBR

Means with the same superscript letter do not differ significantly from each other (ANOVA, Tukey's test, $P>0.05$).

membrane thickness did not significantly differ ($P>0.05$) among the four groups (Table 2; Figure 1).

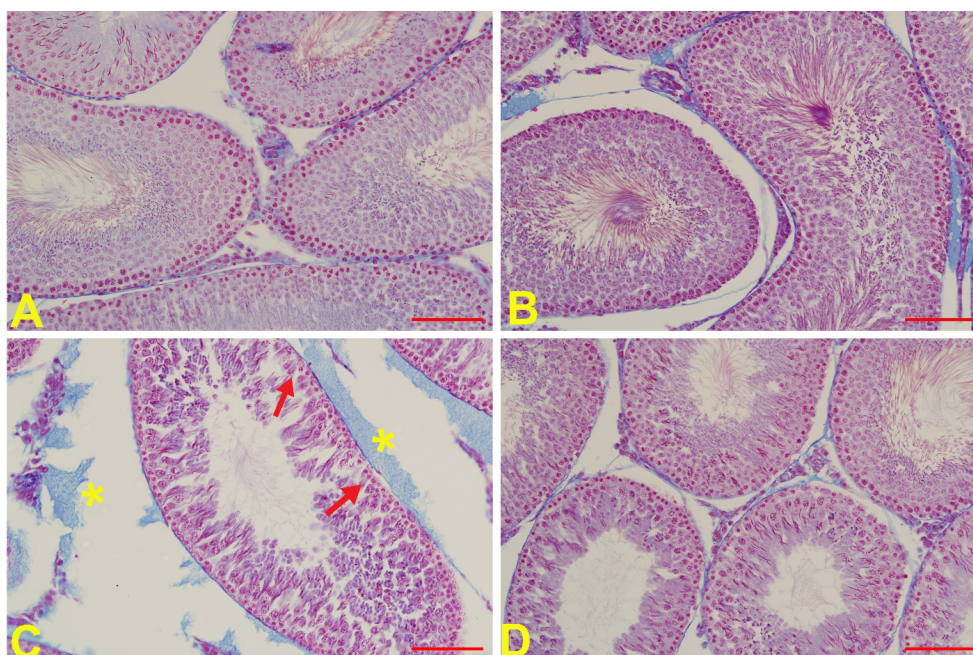
Number of the spermatogonia cells, spermatocyte, spermatid, and sertoli cells

A significant decline in the mean count of spermatogonia, spermatocyte, spermatid, and Sertoli cells was detected in the sodium arsenite group compared to the control group ($P=0.04$). In contrast, the parameters mentioned above did not change in the sodium arsenite +Vit C group compared with the control group ($P>0.05$) (Table 2). The sole treatment with Vit C leads to a sig-

nificant ($P=0.01$) rise in the mean number of spermatogonia cells, spermatocytes, and spermatid compared to the other groups (Table 2).

Daily sperm production

The average daily production of sperm in mice treated with sodium arsenite was significantly declined compared to the control ($P=0.038$). Also, in the sodium arsenite+Vit C group, the daily production of sperm was significantly increased and reached the control level ($P=0.01$). In addition, the average daily production of



PBR

Figure 1. Micrographs of testis tissue in different groups of mice after 35 days of treatment

A) The control group, presenting a typical number of sperm and a germinal epithelium with a typical height and regular arrangement; B) The Vit C group (150 mg/kg/d) showing the average amount of sperm and a germinal epithelium with normal height and regular arrangement; C) The sodium arsenite group (7 mg/kg/d), showing a reduction in the amount of sperm with an irregular and vacuolated germinal epithelium and the formation of giant cells due to the degeneration of the germinal epithelium (arrows) and creation of intermediate tissue edema (asterisk); D) The sodium arsenite+Vit C (150 mg/kg/d) group, indicating an increase in the number of sperm with a more regular arrangement of germinal epithelium compared to the sodium arsenite group (Sections with 5 μ m thickness and Heidenhain Azan staining, $\times 100$) (Scale bars: 100 μ m).

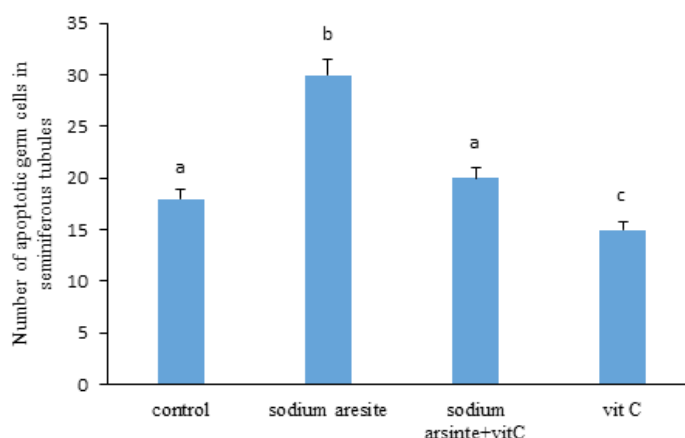


Figure 2. Assessment of apoptosis induced by sodium arsenite and Vit C by TUNEL assays

PBR

As shown in the diagram, in the sodium arsenite group, the number of positive apoptotic cells in the testicular tubules significantly increased compared to the control group. But in the sodium arsenite+Vit c group, the number of positive apoptotic cells in the testicular tubules decreased significantly compared to the sodium arsenite group. In addition, in the Vit C group, the number of positive apoptotic cells in the testicular tubules decreased significantly compared to the control group (Values are presented as Mean±SD. Means with the same code letter do not differ significantly from each other (ANOVA, Tukey's test, $P>0.05$).

sperm was significantly increased in the Vit C group compared to the control group ($P=0.004$) (Table 2).

arsenite+Vit C groups. However, it did not significantly change compared to the control group (Figures 2 and 3).

Measurement of Malondialdehyde (MDA) level

The serum and testicular concentrations of MDA were significantly increased in the sodium arsenite group compared with the control group ($P=0.04$). At the same time, MDA level significantly decreased in the sodium-arsenite +Vit C group than the sodium arsenite group ($P=0.03$) (Table 3) and reached the control level in the case of testicular level of MDA.

Discussion

Our study results from the histopathological examinations on the testes illustrated a significant decline in the group treated with sodium arsenite. Also the level of testosterone was reduced which has the main role in spermatogenesis, while the level of MDA and TUNEL-positive cells was increased. On the other hand, Vit C treatment, contrary to the sodium arsenite inducing toxicity, had a protective effect on these parameters.

Analysis of testosterone levels

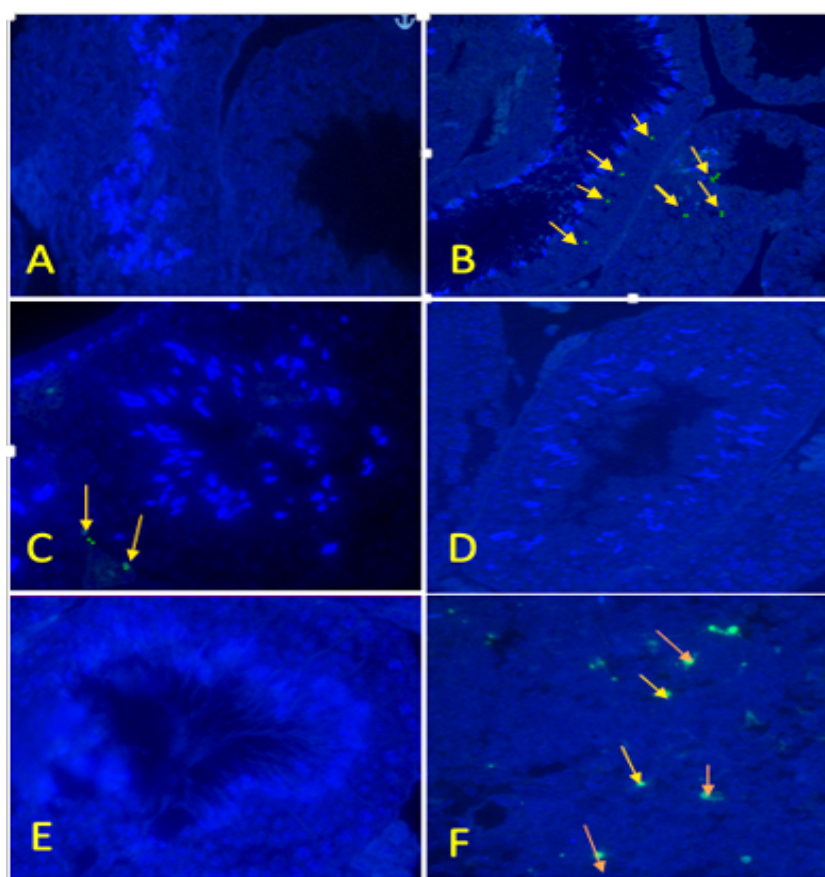
The comparison of the serum level of testosterone in different groups of mice revealed a significant decrease in the sodium arsenite group than the control group ($P=0.001$). In contrast, the mentioned parameter indicated a significant increase in the sodium arsenite +Vit C group compared to the arsenite sodium group ($P=0.01$) and reached the control level (Table 3).

In the current study, we found that the testis and body weight of mice exposed to sodium arsenite did not significantly differ among the groups. Nonetheless, previous research has indicated a reduction in the body and testis weight following arsenic exposure [20, 21]. This difference in results can be due to the treatment duration and the time-dependent toxicity of sodium arsenite.

Apoptosis of the germ cells

In mice treated with sodium arsenite, there was a significant rise in the count of TUNEL-positive cells ($P=0.03$) compared to other groups. Treatment with sodium arsenite+Vit C caused a significant decline in the count of TUNEL-positive cells compared to the sodium arsenite-treated mice ($P=0.01$). Moreover, the count of apoptotic cells was significantly decreased in the VitC group ($P=0.04$) compared with the sodium arsenite and sodium

The findings from the present study showed that sodium arsenite significantly reduced the height and the diameter of the epithelium of the seminiferous tubules and the sperm tail length. Other studies [22] have also revealed that sodium arsenite causes undesired histopathological changes and atrophy of the seminiferous tubules, which is due to sodium arsenite-induced oxidative stress. Since seminal tubules are components of the testicles, a decrease in the volume of the seminiferous tubules can reduce the testis volume [23], which is in accordance with our findings. Also, our data revealed that treatment



PBR

Figure 3. Effect of Vit C on sodium arsenite-induced on the number of apoptotic cells by fluorescence microscope (x400)

A) Control, B) Treated with sodium arsenite, C) Treated with Vit C, D) Treated with sodium arsenite+Vit C. Compared With The Control Group, the number of apoptotic cells was significantly increased in the sodium arsenite group. The apoptotic cells (green) can be recognized. In the testes of negative control mice, have non-apoptotic cells is observed (E). In the positive control (the thymus of the mouse), apoptotic cells are well characterized (F).

with sodium arsenite significantly decreased the count of spermatogenic cells such as spermatogonia, spermatocyte, spermatid cells, and Sertoli cells. Various studies have also obtained similar results [24], confirming the adverse influence of sodium arsenite on the male reproductive system due to its induced oxidative stress [25]. Sodium arsenite will diminish the activity of gonadotropins by increasing the level of corticosteroids, which consequently lowers the level of Follicle-Stimulating Hormone (FSH), Luteinizing Hormone (LH), and testosterone [26]. These hormones are essential for initiating and maintaining spermatogenesis [26, 27]. Therefore, the reduction found in the number of germ cells may be due to the impaired function of the hypothalamus and the pituitary axis [5]. In addition, sodium arsenite disturbs the synthesis of essential enzymes required for cell metabolism by binding to the carbonyl and sulfhydryl groups of proteins and inhibiting different transcription factors [28], which could be considered another reason

explaining the reduced number of germ cells following exposure to sodium arsenite.

We also demonstrated a significant reduction in the sperm characteristics, including count, motility, and viability in mice treated with sodium arsenite, reported by other studies [27, 29]. As mentioned above, the reduction in sperm and its daily production may be due to decreased levels of hormones such as FSH, LH, and testosterone [26]. Moreover, Khan et al. reported that treatment with sodium arsenite would increase apoptosis and cell death in the testis of mature mice [30]. Lipid peroxidation occurring as a result of sodium arsenite-induced oxidative stress disturbs the permeability of the sperm membrane and also the potential of the mitochondrial membrane, causing the release of apoptotic factors, such as cytochrome C, from the mitochondria [31]. Sodium arsenite also induces apoptosis and cell death by increasing the Bax gene expression and reducing the Bcl2 gene expression, as well as activating caspase-9 and caspase-3

[32]. These events explain the reduction in cell viability in the sodium arsenite group. Sodium arsenite also disrupts the phosphorylation of Adenosine triphosphate (ATP) in the mitochondrial membrane, resulting in ATP and sperm motility reduction [31]. Our findings also support this outcome.

Our data also revealed an increase in the percentage of abnormal sperms in the sodium arsenite group, which could be due to induced oxidative stress factors and ROS production. In the present study, treatment with sodium arsenite significantly increased the MDA levels, which agrees with the previous studies [33]. Sodium arsenite increased the production of free radicals and decreased the intracellular antioxidant activity, resulting in a loss of antioxidant balance, and eventually lipid peroxidation and increased levels of MDA [34].

Vitamin C is a water-soluble vitamin that is part of the antioxidant system of the seminal fluid [35] and is very important in normal body performance [33]. The data from the current study showed that Vit C significantly increased the height and diameter of the epithelium seminiferous tubules and the number of germ cells, including the spermatogonia, spermatocyte, spermatid, and Sertoli cells in the sodium arsenite+Vit C group. This finding has been reported by previous studies, too [36]. In addition, our findings indicated a significant increase in daily sperm production as well as other sperm parameters in mice treated with sodium arsenite+Vit C.

The levels of ascorbic acid in the semen plasma is 8 to 10 times higher than the blood level, and this high concentration of Vit C in the seminal plasma, as a ROS scavenger, plays an important role in maintaining the DNA integrity and protecting the male germ cells against oxidative stress [37]. This finding can prove the increase in the sperm number and motility and the decrease in the number of abnormal sperm in the sodium arsenite+Vit C group.

We also found a significant decrease in MDA levels in the arsenite +Vit C group, which is in accordance with the findings of other studies [38]. Considering the antioxidant nature of Vit C, it can reduce the level of free radicals and lipid peroxidation in the blood serum and testicular tissue of mice treated with sodium arsenite [38]. Moreover, the administration of Vit C caused a significant increase in the levels of testosterone which is in line with the findings of Karanth et al. [39]. They reported that Vit C activates the FSH and LH secretion from the anterior pituitary gland and causes the release of testosterone from the Leydig cells. Our results also indicated the reduction in the number of apoptotic cells

in the arsenite+Vit C group, which has also been shown by other studies [40]. This finding emphasizes that Vit C can protect the germ cells from apoptosis and is essential for the scavenging system and counteract the effects of oxidative stress.

Conclusion

Our findings show that Vit C can compensate for the adverse effects of sodium arsenite on sperm parameters, spermatogenesis, and testosterone levels in adult mice. So its consumption can be suggested in populations exposed to sodium arsenite to prevent its disturbing consequences.

Ethical Considerations

Compliance with ethical guidelines

The study was approved by the Animal Ethics Committee of the Qom University (IR.QOM.REC.1399.012), Qom City. All ethical principles were observed in this article.

Funding

This research did not receive any grant from funding agencies in the public, commercial, or non-profit sectors.

Authors' contributions

Conceptualization and Supervision: Ebrahim Cheraghi, Hamid Piroozmanesh, and Malek Soleimani Mehranjani; Investigation, Writing – original draft, and Writing – review & editing: All authors; Data collection: Hamid Piroozmanesh; Data analysis: Ebrahim Cheraghi, Hamid Piroozmanesh, Malek Soleimani Mehranjani; Funding acquisition and Resources: Ebrahim Cheraghi, Malek Soleimani Mehranjani.

Conflict of interest

The authors declared no conflict of interest.

Acknowledgments

We thank the members of the Department of Biology, Arak University that supported this research.

References

- [1] Ilić BS, Kolarević A, Kocić G, Šmelcerović A. Ascorbic acid as DNase I inhibitor in prevention of male infertility. *Biochem*

- Biophys Res Commun. 2018; 498(4):1073-7. [DOI:10.1016/j.bbrc.2018.03.120] [PMID]
- [2] Pant N, Murthy RC, Srivastava SP. Male reproductive toxicity of sodium arsenite in mice. *Hum Exp Toxicol*. 2004; 23(8):399-403. [DOI:10.1191/0960327104ht4670a] [PMID]
 - [3] Xu Y, Fu J, Wang H, Hou Y, Pi J. Arsenic exposure and life-style-related diseases. In: Yamauchi H, Sun G, editors. *Arsenic Contamination in Asia. Current Topics in Environmental Health and Preventive Medicine*. Singapore: Springer; 2019. pp. 83-118. [DOI:10.1007/978-981-13-2565-6_6]
 - [4] Kenfack A, Ngoula F, Chombong JK, Vemo NB, Ndikum JA, Ngouateu OB, et al. Effects of propoxur on male fertility in Wistar rat exposed neonatally. *Int J Reprod Contracept Obstet Gynecol*. 2014; 3(4):898-902. [DOI:10.5455/2320-1770.ijrcog20141205]
 - [5] Souza ACF, Marchesi SC, Ferraz RP, de Almeida Lima GD, de Oliveira JA, Machado-Neves M. Effects of sodium arsenate and arsenite on male reproductive functions in Wistar rats. *J Toxicol Environ Health A*. 2016; 79(6):274-86. [DOI:10.1080/15287394.2016.1150926] [PMID]
 - [6] Sönmez M, Türk G, Yüce A. The effect of ascorbic acid supplementation on sperm quality, lipid peroxidation and testosterone levels of male Wistar rats. *Theriogenology*. 2005; 63(7):2063-72. [DOI:10.1016/j.theriogenology.2004.10.003] [PMID]
 - [7] Ali WAG, Mohammed SA, Abdullah EM, Salah ElDeen EM. Protective effect of vitamin C against aspartame toxicity to the testes: A review article. *Sohag Med J*. 2019; 23(2):52-5. [DOI:10.21608/smj.2019.46424]
 - [8] Leite GAA, Figueiredo TM, Pacheco TL, Sanabria M, e Silva PV, Fernandes FH, et al. Vitamin C partially prevents reproductive damage in adult male rats exposed to rosvastatin during prepuberty. *Food Chem Toxicol*. 2017; 109(Pt 1):272-83. [DOI:10.1016/j.fct.2017.09.003] [PMID]
 - [9] Eskenazi B, Kidd SA, Marks AR, Slotter E, Block G, Wyrobek AJ. Antioxidant intake is associated with semen quality in healthy men. *Hum Reprod*. 2005; 20(4):1006-12. [DOI:10.1093/humrep/deh725] [PMID]
 - [10] Yousef MI, Abdallah GA, Kamel KI. Effect of ascorbic acid and vitamin E supplementation on semen quality and biochemical parameters of male rabbits. *Anim Reprod Sci*. 2003; 76(1-2):99-111. [DOI:10.1016/S0378-4320(02)00226-9]
 - [11] Abu Zeid EH, Hussein MMA, Ali H. Ascorbic acid protects male rat brain from oral potassium dichromate-induced oxidative DNA damage and apoptotic changes: The expression patterns of caspase-3, P 53, Bax, and Bcl-2 genes. *Environ Sci Pollut Res Int*. 2018; 25(13):13056-66. [DOI:10.1007/s11356-018-1546-9] [PMID]
 - [12] Bustos-Obregón E, Poblete D, Catriao R, del Sol M, Fernandes FH. Melatonin protective role in mouse cauda epididymal spermatozoa damage induced by sodium arsenite. *Int J Morphol*. 2013; 31(4):1251-6. [DOI:10.4067/S0717-95022013000400017]
 - [13] El-Sayed MF, Abdel-Ghaffar SK, Adly MA, Abdo Salim A, Abdel-Samei WM. The ameliorative effects of DMSA and some vitamins against toxicity induced by lead in the testes of albino rats. II. *J Basic Appl Zool*. 2015; 71:60-5. [DOI:10.1016/j.jobaz.2015.05.003]
 - [14] Oyeyemi WA, Kolawole TA, Shittu ST, Ajah R, Oyeyemi BF. Effects of ascorbic acid on reproductive functions of male Wistar rats exposed to nicotine. *J Afr Assoc Physiol Sci*. 2014; 2(2):110-16. <https://www.ajol.info/index.php/jaaps/article/view/132672>
 - [15] Bearden HJ, Fuquay JW. *Applied Animal Reproduction*. New Jersey: Prentice Hall. 1992. https://www.google.com/books/edition/Applied_Animal_Reproduction/=en
 - [16] Gurr E. *Staining animal tissues: Practical and theoretical*. London: Leonard Hill; 1962. pp. 170-330. <https://books.google.com/books?id=vrEKAQAAMAAJ&dq>
 - [17] Soleimani Mehranjani M, Taefi R. The protective role of vitamin E on the testicular tissue in rats exposed to sodium arsenite during the prenatal stage till sex maturity: A stereological analysis. *Iran J Reprod Med*. 2012; 10(6):571-80. [PMCID]
 - [18] Buege JA, Aust SD. Microsomal lipid peroxidation. In: Fleischer S, Packer L, editors. *Biomembranes - Part C: Biological Oxidations. Methods in Enzymology*. Vol. 52. Amsterdam: Elsevier; 1978. pp. 302-310. [DOI:10.1016/S0076-6879(78)52032-6]
 - [19] Negoescu A, Lorimier P, Labat-Moleur F, Drouet C, Robert C, Guillemet C, et al. In situ apoptotic cell labeling by the TUNEL method: Improvement and evaluation on cell preparations. *J Histochem Cytochem*. 1996; 44(9):959-68. [DOI:10.1177/44.9.8773561] [PMID]
 - [20] Fouad AEA, Fouad AA, Al-Melhim WN. Protective effect of baicalin in rats exposed to arsenic-induced testicular toxicity. *Indian J Forensic Med Toxicol*. 2018; 12(2):256-61. <https://www.ijfmr.com/scripts/IJFMR%20April-June%202018%20.pdf>
 - [21] Mamoun M, Qazi S, Alamgir I. Reduction of body and testicular weight of albino rats in arsenic toxicity. *Ann Punjab Med Coll*. 2018; 12(3):173-5. <https://pesquisa.bvsalud.org/portal/resource/pt/emr-206595>
 - [22] de Araújo Ramos AT, Diamante MAS, de Almeida Lamas C, Dolder H, de Souza Predes F. Morphological and morphometrical changes on adult Wistar rat testis caused by chronic sodium arsenite exposure. *Environ Sci Pollut Res Int*. 2017; 24(36):27905-12. [DOI:10.1007/s11356-017-0200-2] [PMID]
 - [23] Mehrzadi S, Bahrami N, Mehrabani M, Motevalian M, Mansouri E, Goudarzi M. Ellagic acid: A promising protective remedy against testicular toxicity induced by arsenic. *Biomed Pharmacother*. 2018; 103:1464-72. [DOI:10.1016/j.biopha.2018.04.194] [PMID]
 - [24] Cheema HW, Ali Sh, Beenish H, Khurshid T. The ameliorative effect of olive oil on arsenic induced hepatic gross and qualitative histological changes in albino rats. *Isra Med J*. 2019; 11(4):213-7. <http://www.imj.com.pk/wp-content/uploads/2019/10/3-OA-988The-ameliorative-of-.pdf>
 - [25] Uygur R, Aktas C, Caglar V, Uygur E, Erdogan H, Ozen OA. Protective effects of melatonin against arsenic-induced apoptosis and oxidative stress in rat testes. *Toxicol Ind Health*. 2016; 32(5):848-59. [DOI:10.1177/0748233713512891] [PMID]
 - [26] Jana K, Jana S, Samanta PK. Effects of chronic exposure to sodium arsenite on hypothalamo-pituitary-testicular activities in adult rats: Possible an estrogenic mode of action. *Reprod Biol Endocrinol*. 2006; 4:9. [DOI:10.1186/1477-7827-4-9] [PMCID]

- [27] Chang SI, Jin B, Youn P, Park Ch, Park JD, Ryu DY. Arsenic-induced toxicity and the protective role of ascorbic acid in mouse testis. *Toxicol Appl Pharmacol*. 2007; 218(2):196-203. [DOI:10.1016/j.taap.2006.11.009] [PMID]
- [28] Sanghamitra S, Hazra J, Upadhyay SN, Singh RK, Amal RC. Arsenic induced toxicity on testicular tissue of mice. *Indian J Physiol Pharmacol*. 2008; 52(1):84-90. [PMID]
- [29] Pant N, Kumar R, Murthy RC, Srivastava SP. Male reproductive effect of arsenic in mice. *Biometals*. 2001; 14(2):113-7. [DOI:10.1023/A:1016686113763] [PMID]
- [30] Khan S, Telang A, Malik J. Arsenic-induced oxidative stress, apoptosis and alterations in testicular steroidogenesis and spermatogenesis in Wistar rats: Ameliorative effect of curcumin. *Wudpecker J Pham Pharmacol*. 2013; 2:33-48. <https://www.semanticscholar.org/paper/Arsenic-induced-2c2c2f>
- [31] Zubair M, Ahmad M, Saleemi MK, Gul ST, Ahmad M, Martyniuk CJ, et al. Sodium arsenite toxicity on hematology indices and reproductive parameters in Teddy goat bucks and their amelioration with vitamin C. *Environ Sci Pollut Res Int*. 2020; 27(13):15223-32. [DOI:10.1007/s11356-020-08049-z] [PMID]
- [32] Manna P, Sinha M, Sil PC. Protection of arsenic-induced testicular oxidative stress by arjunolic acid. *Redox Rep*. 2008; 13(2):67-77. [DOI:10.1179/135100008X259169] [PMID]
- [33] Said TM, Fischer-Hammadeh C, Hamad M, Refaat Kh, Hammadeh ME. Oxidative stress, DNA damage, and apoptosis in male infertility. In: Agarwal A., Aitken R., Alvarez J, editors. *Studies on Men's Health and Fertility. Oxidative Stress in Applied Basic Research and Clinical Practice*. Totowa, NJ: Humana Press; 2012. pp. 433-448. [DOI:10.1007/978-1-61779-776-7_20]
- [34] Alani GT, Khonda SS, El Yaseen HD. Analysis of DNA damage and oxidative stress in human spermatozoa and some biochemical changes in seminal plasma and their correlation with semen quality of infertile men. *Iraqi Postgraduate Med J*. 2011; 10(1):81-8. https://www.researchgate.net/publication/328162435_SEMEN_QUALITY
- [35] Adewoyin M, Ibrahim M, Roszaman R, Md Isa ML, Alewi NAM, Rafa AAA, et al. Male infertility: The effect of natural antioxidants and phytochemicals on seminal oxidative stress. *Diseases*. 2017; 5(1):9. [DOI:10.3390/diseases5010009] [PMID] [PMCID]
- [36] El Shafai A, Zohdy N, El Mulla Kh, Hassan M, Morad N. Light and electron microscopic study of the toxic effect of prolonged lead exposure on the seminiferous tubules of albino rats and the possible protective effect of ascorbic acid. *Food Chem Toxicol*. 2011; 49(4):734-43. [DOI:10.1016/j.fct.2010.11.033] [PMID]
- [37] Azari O, Gholipour H, Kheirandish R, Babaei H, Emadi L. Study of the protective effect of vitamin C on testicular tissue following experimental unilateral cryptorchidism in rats. *Andrologia*. 2014; 46(5):495-503. [DOI:10.1111/and.12106] [PMID]
- [38] Metwally MAA, Fouad IM. Effects of L-ascorbic acid on sperm viability in male grass carp (*Ctenopharyngodon idellus*). *Glob Vet*. 2009; 3(2):132-6. [http://www.idosi.org/gv/gv3\(2\)09/10.pdf](http://www.idosi.org/gv/gv3(2)09/10.pdf)
- [39] Karanth Sh, Yu WH, Walczewska A, Mastronardi CA, McCann SM. Ascorbic acid stimulates gonadotropin release by autocrine action by means of NO. *Proc Natl Acad Sci U S A*. 2001; 98(20):11783-8. [DOI:10.1073/pnas.191369398] [PMID] [PMCID]
- [40] Shete SA, Hamid M. Antioxidant level in the seminal plasma of human subjects with different fertility potential. *Natl J Physiol Pharm Pharmacol*. 2016; 6(1):93-6. [DOI:10.5455/njppp.2015.5.2010201587]