

Case Report: Healthy Baby Delivery of a COVID-19 Infected Mother in Iran: Process and Protection



Hamideh Abbaspour Kasgary¹ , Parisa Moradimajd² , Hamidreza Samaei^{3*} , Lotfollah Davoodi⁴

1. Department of Clinical Pharmacy, School of Pharmacy, Mazandaran University of Medical Sciences, Sari, Iran.

2. Department of Anesthesia, School of Allied Medical Sciences, Iran University of Medical Sciences, Tehran, Iran.

3. Department of Clinical Pharmacy, School of Pharmacy, Mazandaran University of Medical Sciences, Sari, Iran.

4. Department of Infectious Disease, School of Medicine, Antimicrobial Resistance Center, Ghaemshahr Razi Hospital, Mazandaran University of Medical Sciences, Sari, Iran.

* Corresponding Author:

Hamidreza Samaee, PhD.

Address: Department of Clinical Pharmacy, School of Pharmacy, Mazandaran University of Medical Sciences, Sari, Iran.

Phone: +98 (913) 2612242

E-mail: hrsamaee@yahoo.com



Copyright© 2020, The Authors.

Article info:

Received: 29 Jul 2020

Accepted: 28 Feb 2021

Keywords:

SARS-CoV-2, COVID-19,
Pregnant woman, Delivery

ABSTRACT

Background: In late December 2019, a kind of pneumonia caused by a novel coronavirus (SARS-CoV-2) emerged in Wuhan, Hubei Province, China. This virus rapidly spread worldwide and infected 195 countries and territories, including Iran. By March 22, 2020, the virus had affected more than 40000 people worldwide and caused more than 19000 deaths. Pregnant women are a vulnerable group to viral infections because partial immune suppression occurs during pregnancy. Therefore, the COVID-19 epidemic may cause a rising global concern about its consequences for pregnant women and fetuses.

Objectives: In this case study, we report the delivery of a pregnant woman after her COVID-19 confirmation.

Methods: We report a 44-year-old pregnant woman (32 weeks gestation) with COVID-19 who gave birth to a healthy baby with no evidence of COVID-19. We did not observe any worse clinical outcomes, such as maternal mortality, stillbirth, spontaneous abortion, and preterm delivery.

Results: A preterm baby girl with 2500 g weight and Apgar scores at 5 minutes and 10 minutes were 9 and 10 was delivered. The preterm baby was normocephalic, had no icteric sclera, and the heart sounded normal without murmurs, Lung ventilation was normal.

Conclusion: Viral pneumonia may severely be presented in pregnancy because of physiological and immunological changes and shift from cell-mediated to humoral-mediated immunity during the pregnancy period. Vertical transmission of COVID-19 from mother to child, short-term and long-term adverse effects on mother and newborn are still unclear and controversial.

Citation Abbaspour Kasgary H, Moradimajd P, Samaei HR, Davoodi L. Healthy Baby Delivery of a COVID-19 Infected Mother in Iran: Process and Protection. Pharmaceutical and Biomedical Research. 2021; 7(4):323-328. <http://dx.doi.org/10.18502/pbr.v7i4.9370>

<http://dx.doi.org/10.18502/pbr.v7i4.9370>

Introduction

In late December 2019, a kind of pneumonia caused by a novel coronavirus (SARS-CoV-2) emerged in Wuhan, Hubei Province, China [1, 2]. Respiratory droplet is the main route of SARS-CoV-2 transmission. Also, it can be transmitted through close contact from person to person [2-4]. The virus rapidly spread worldwide and infected more than 200 countries and territories, including Iran. By October 7, 2020, this virus affected more than 36000000 people worldwide and caused more than 1000000 deaths [5].

Pregnant women are a vulnerable group to viral infections because partial immune suppression occurs in pregnancy [6]. According to the previous studies, pregnant women are at higher risk for H1N1, SARS-CoV, MERS-CoV, and the Ebola virus [7, 8]. Also, there are reports of adverse clinical outcomes in pregnancy and labor, such as maternal morbidity and mortality, stillbirth, spontaneous abortion, and complicated delivery [6-13]. Therefore, the COVID-19 epidemic created global concern about its consequences for pregnant women and fetuses. Until now, there is not enough data about the effect of novel coronavirus (SARS-CoV-2) infection on the fetus and postpartum complications.

We present a 42-year-old pregnant woman (34 weeks gestation) with COVID-19 that gave birth to a healthy baby with no evidence of COVID-19 in Iran.

Case Report

This case is a 44-year-old pregnant woman (32 weeks gestation, 80 kg weight, and 164 cm height) who lives in Mazandaran Province, Iran. She got pregnant through in vitro fertilization (IVF). The mother has gestational diabetes and has been injected with subcutaneous insulin. She had a history of hypothyroidism treated with levothyroxine. This patient had no history of hypertension, heart disease, allergy, or abortion.

On March 19, 2020, the woman was transferred to the Emergency Department with dyspnea, fever, and shivering. The patient had a dry cough. On admission, her vital signs were as follows: temperature= 38.4°C, blood pressure= 105/65 mm Hg, heart rate= 122 beats per minute, respiratory rate=28 breaths per minute, and SpO₂= 93%. The triage level was 2 based on the ESI (emergency severity index) triage scale. The patient's initial evaluation revealed her history of contact with a family member with COVID-19 disease. Because of suspected

COVID-19 symptoms, a preliminary CT scan was asked for the assessment of this patient. Also, swap samples were taken from the nose and throat for the RT-PCR test. The CT result after a few hours showed ground-glass opacities in the right upper and lower lobes. Blood tests are presented in Table 1. The maternal RT-PCR test for SARS-CoV-2 was positive.

After confirming infection with COVID-19, she was transferred to the intensive care unit (ICU) and stayed there for 3 days (19 to 22 March). On admission to ICU, her body temperature was 38°C, her blood pressure was 111/80 mm Hg, with a respiratory rate of 22 breaths per minute, and pulse rate of 115 beats per minute. She had a dry cough without sputum. Fetal heart rate (FHR) was 140 beats per minute, and fetal monitoring showed no abnormality. Hydroxychloroquine 200 mg PO BD and azithromycin were started for the patient. These drugs were prescribed based on the approved protocol of Iran drug administration for pregnant women. According to this protocol, only oseltamivir and chloroquine can be used [14].

Two days later, gynecologists decided to end the pregnancy after considering the mother's situation. Cesarean section was performed under regional anesthesia (spinal). The patient wore an N95 mask during the operation. Measures in all phases of labor and post-labor were taken to reduce the risk of infection based on guidelines for pregnant women with suspected SARS-CoV-2 infection published on March 3, 2020 [9, 14].

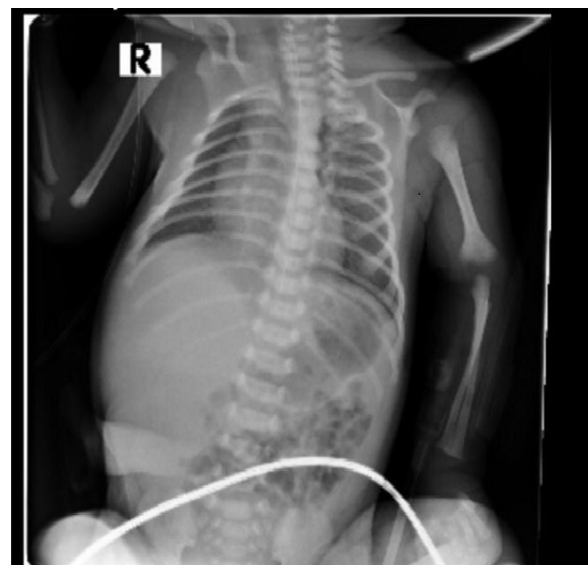


Figure 1. Chest X-ray of the newborn obtained on March 22, 2020

Showing clear and normal lung texture with no abnormalities in heart and palate

Table 1. Laboratory results of the mother

Patient Parameter	Admission	Third Day (Labor)
Lymphocyte (number/ μ L)	1400 (13.3%)	1200 (8.5%)
Neutrophil (number/ μ L)	7400 (74%)	11900 (83%)
WBC (number/ μ L)	10300	14300
Red Blood Cel (number/ μ L)	3360000	3370000
Platelet (number/ μ L)	254000	264000
Lactate Dehydrogenase (IU/l)	875	877
Creatine phosphokinase	50	51
Fasting Blood Sugar (mg/dL)	97	82
Na (mEq/L)	145	143
K (mEq/L)	4.9	4.8
Blood urea nitrogen (mg/dL)	15	14
Cr (mg/dL)	1.1	1.1
Hematocrit (%)	29.7	29.9
Hemoglobine (g/dL)	9.8	9.7
Prothrombin Time (min)	16.2	16.3
Partial Thromboplastin Time	41	40
International normalised ratio	1.63	1.54
Aspartate transaminase (Umol/L)	63	62
Alanine transaminase (Umol/L)	45	44
Alkaline phosphatase (U/L)	431	430

At 10:35 PM, a preterm baby girl was delivered. The baby's weight was 2500 g and her Apgar scores at 5 minutes and 10 minutes were 9 and 10, respectively. The preterm baby was normocephalic, had no icteric sclera, and the heart sounded normal without murmurs. Lung ventilation was normal and clear, without rales and crackles.

Then, the baby was transferred to the neonate intensive care unit (NICU). Her vital signs in NICU admission were as follows: temperature=36.2°C, blood pressure= 66/36 mm Hg, heart rate= 123 beats per minute, respiratory rate= 74 breaths per minute, and SpO₂= 86%. Table 2 presents the laboratory data. Arterial blood gases (ABG) results were normal (pH=7.32, PaCO₂=43.7 mm Hg, PaO₂=58 mm Hg, HCO₃=23 mEq/L, SpO₂=78.6%. BE= -3.2) without acidosis or alkalosis. After 2 days stay in NICU, the hemodynamic situation of the pre-

term neonate was stable, and her nasopharyngeal swap for SARS-CoV-2 RT-PCR obtained 16 hours after the delivery came back negative. Also, the chest x-ray of the newborn showed a typical presentation (Figure 1).

On March 25, the mother was discharged from the gynecological ward without complications. Her laboratory tests were normal (Table 1), and ABG results were as follows: pH=7.38, PaCO₂=29.4 mm Hg, PaO₂=98 mmHg, HCO₃=17.6 mEq/L, and SpO₂=97%.

Discussion

Influenza is a severe disease for pregnant women and may cause complications for the mother and fetus. In recent years, vaccines have been given to pregnant women due to the seasonal outbreak of the flu [7]. COVID-19 is

Table 2. Laboratory results of the newborn

Parameter	Admission on NICU
Lymphocyte (number/ μ L)	5800 (41.2%)
Neutrophil (number/ μ L)	7200 (51.9%)
Bil (mg/dL)	7.5
WBC (number/ μ L)	14000
RBC (number/ μ L)	4790000
PLT (number/ μ L)	201000
LDH (IU/l)	1119
CPK1	526
FBS (mg/dL)	120
Na (mEq/L)	137
K (mEq/L)	6.2
Ca (mEq/L)	9.9
BUN (mg/dL)	15
Creatinine (mg/dL)	0.7
HCT (%)	50.2
Hb (g/dL)	17.7
AST (Umol/L)	45
ALT (Umol/L)	18
ALP(U/L)	287

PBR

a novel coronavirus that rapidly spreads and may affect pregnant women [7-12]. We report the first case of neonatal COVID-19 infection in a referral center for managing COVID-19 in Mazandaran Province, Iran. The baby's mother was infected with COVID-19. After labor, the clinical manifestations of the mother were moderate, and the baby's prognosis was satisfactory.

Until now, the consequences of infection with SARS-CoV-2 for pregnancies have remained uncertain [10, 13]. Yu et al. compared the hematological characteristic of SARS-CoV-2 with SARS-CoV-1 and, based on the similarity, concluded that the risk of vertical transmission of the COVID-19 virus is low [14]. But as stated before, there is not enough evidence of clinical characteristics and vertical transmission in pregnancy and labor. As previously reported, the clinical characteristics of this pregnant woman were similar to non-pregnant adults

with COVID-19 [3, 13]. The present case manifested the same signs and symptoms, such as fever, dry cough, and dyspnea. But we cannot claim that all pregnant women present with the same manifestations.

The published case reports and other studies have reported different results about healthy or infected newborns of COVID-19-infected mothers. However, some studies indicated that the maternal, fetal, and neonatal outcomes of infected patients in late pregnancy appeared good, and the infection was not transmitted from mother to infant [11-15]. But the study of Zhu et al. in China on 19 pregnant women showed that COVID-19 might have adverse effects on newborns, causing problems such as fetal distress, premature labor, respiratory distress, thrombocytopenia accompanied by abnormal liver function, and even death [12]. David A. Schwartz assessed

38 pregnant women with COVID-19 and concluded that anyone could be affected with COVID-19 [16].

Based on the early reports in this epidemic, there were two cases of neonatal SARS-CoV-19 infection that had no direct evidence for vertical transmission. However, one was an infant diagnosed at 17 days of life having a history of close contact with 2 confirmed cases of SARS-CoV-2 infection (mother and nanny), and the other was a neonate who was found to be infected 36 hours after delivery. According to the reports, viral testing was delayed, and infection may be acquired postpartum through an infected contact (nosocomial infection) [17, 18]. However, management of pregnant women with COVID-19 in the first and second trimester of pregnancy regarding the transmission and drug prescription is challenging and needs further study.

Conclusion

Because of the physiological and immunological changes and shift from cell-mediated to humoral-mediated immunity in pregnancy, viral pneumonia may be severe in pregnant women. Vertical transmission of the COVID-19 virus from mother to child is still unclear. Also, data about short-term and long-term adverse effects on mothers and newborns are still controversial. Fortunately, in this case, the newborn was born healthy, but the risk of long-term harm to the child is unclear, and it will not be known soon. Therefore, we must follow up the newborns and mothers to find the possible effect of COVID-19 on the fetus. Pregnant women must be protected against infection, and more intensive attention to pregnant patients is essential.

Ethical Considerations

Compliance with ethical guidelines

There were no ethical considerations to be considered in this research.

Funding

This research did not receive any grant from funding agencies in the public, commercial, or non-profit sectors.

Authors' contributions

All authors equally contributed to preparing this article.

Conflict of interest

The authors declared no conflict of interest.

Acknowledgments

We are grateful to all staff of Ghaemshahr Razi Hospital for their assistance in conducting and gathering data for this study.

References

- [1] Zhu N, Zhang D, Wang W, Li X, Yang B, Song J, et al. China novel coronavirus investigating and research team. A novel coronavirus from patients with pneumonia in China, 2019. *N Engl J Med.* 2020; 382(8):727-33. [DOI:10.1056/NEJMoa2001017] [PMID] [PMCID]
- [2] Samaee H, Mohsenzadegan M, Ala S, Maroufi SS, Moradimajid P. [Tocilizumab for treatment patients with covid-19: Recommended medication for novel disease (Persian)]. *Int Immunopharmacol.* 2020; 89(Pt A):107018. [DOI:10.1016/j.intimp.2020.107018] [PMID] [PMCID]
- [3] Huang C, Wang Y, Li X, Ren L, Zhao J, Hu Y, et al. Clinical features of patients infected with 2019 novel coronavirus in Wuhan, China. *Lancet.* 2020; 395(10223):497-506. [DOI:10.1016/S0140-6736(20)30183-5] [PMID] [PMCID]
- [4] Wang X, Zhou Z, Zhang J, Zhu F, Tang Y, Shen X. A case of 2019 novel coronavirus in a pregnant woman with preterm delivery. *Clin Infect Dis.* 2020; 71(15):844-6. [DOI:10.1093/cid/ciaa200] [PMID] [PMCID]
- [5] World Health Organization. Situation report-17 situation in numbers total and new cases in last 24 hours [Internet]. 2020 [Cited 2020 Feb 6]. Available from: https://www.who.int/docs/default-source/coronaviruse/situation-reports/20200206-sitrep-17-ncov.pdf?sfvrsn=17f0dca_4
- [6] Liang H, Acharya G. Novel corona virus disease (covid-19) in pregnancy: What clinical recommendations to follow? *Acta Obstet Gynecol Scand.* 2020; 99(4):439-42. [DOI:10.1111/aogs.13836] [PMID]
- [7] Wong SF, Chow KM, Leung TN, Ng WF, Ng TK, Shek CC, et al. Pregnancy and perinatal outcomes of women with severe acute respiratory syndrome. *Am J Obstet Gynecol.* 2004; 191(1):292-7. [DOI:10.1016/j.ajog.2003.11.019] [PMID] [PMCID]
- [8] Creanga AA, Johnson TF, Graitcer SB, Hartman LK, Al-Samarrai T, Schwarz AG, et al. Severity of 2009 pandemic influenza A (H1N1) virus infection in pregnant women. *Obstet Gynecol.* 2010; 115(4):717-26. [DOI:10.1097/AOG.0b013e3181d57947] [PMID]
- [9] Favre G, Pomar L, Qi X, Nielsen-Saines K, Musso D, Baud D. Guidelines for pregnant women with suspected SARS-CoV-2 infection. *Lancet Infect Dis.* 2020; 20(6):652-3. [DOI:10.1016/S1473-3099(20)30157-2] [PMID] [PMCID]
- [10] Favre G, Pomar L, Musso D, Baud D. 2019-nCoV epidemic: What about pregnancies? *Lancet.* 2020; 395(10224):e40. [DOI:10.1016/S0140-6736(20)30311-1] [PMID] [PMCID]
- [11] Liu Y, Chen H, Tang K, Guo Y. Withdrawn: Clinical manifestations and outcome of SARS-CoV-2 infection

- during pregnancy. *J Infect.* 2020; S0163-4453(20)30109-2. [DOI:10.1016/j.jinf.2020.02.028] [PMID] [PMCID]
- [12] Zhu H, Wang L, Fang C, Peng S, Zhang L, Chang G, et al. Clinical analysis of 10 neonates born to mothers with 2019-nCoV pneumonia. *Transl Pediatr.* 2020; 9(1):51-60. [DOI:10.21037/tp.2020.02.06] [PMID] [PMCID]
- [13] Chen H, Guo J, Wang C, Luo F, Yu X, Zhang W, et al. Clinical characteristics and intrauterine vertical transmission potential of covid-19 infection in nine pregnant women: A retrospective review of medical records. *Lancet.* 2020; 395(10226):809-15. [DOI:10.1016/S0140-6736(20)30360-3] [PMID] [PMCID]
- [14] Yu N, Li W, Kang Q, Xiong Z, Wang S, Lin X, et al. Clinical features and obstetric and neonatal outcomes of pregnant patients with covid-19 in Wuhan, China: Aretrospective, single-centre, descriptive study. *Lancet Infect Dis.* 2020; 20(5):559-64. [DOI:10.1016/S1473-3099(20)30176-6] [PMID] [PMCID]
- [15] Alserehi H, Wali G, Alshukairi A, Alraddadi B. Impact of middle east respiratory syndrome coronavirus (mers-cov) on pregnancy and perinatal outcome. *BMC Infect Dis.* 2016; 16:105. [DOI:10.1186/s12879-016-1437-y] [PMID] [PMCID]
- [16] Schwartz DA. An analysis of 38 pregnant women with covid-19, their newborn infants, and maternal-fetal transmission of SARS-CoV-2: Maternal coronavirus infections and pregnancy outcomes. *Arch Pathol Lab Med.* 2020; 144(7):799-805. [DOI:10.5858/arpa.2020-0901-SA] [PMID]
- [17] Qiao J. What are the risks of covid-19 infection in pregnant women? *Lancet.* 2020; 395(10226):760-2. [DOI:10.1016/S0140-6736(20)30365-2] [PMID] [PMCID]
- [18] Schwartz DA, MD, MS Hyg, FCAP. Covid-19, SARS-CoV-2 and pregnancy: Does the past predict the present? [Internet]. 2020 [Cited 2020 Feb 29]. Available from: <https://www.contagionlive.com/view/covid19-sarscov2-and-pregnancy-does-the-past-predict-the-present>