

Comparison of leeching and heparin therapy in management of acute venous congestion of limbs in rat

Seyed Abdollah Mousavi^{1*}, Maryam Ghasemi², Seyed Jaber Mousavi³, Seyyed Saied Mousavi Darka⁴, Vafa Bagheri⁵

¹Department of Pediatric Surgery, Faculty of Medicine, Mazandaran University of Medical Sciences, Sari, Iran

²Department of Pathology, Faculty of Medicine, Mazandaran University of Medical Sciences, Sari, Iran

³Community Medicine Research Center, Mazandaran University of Medical Sciences, Sari, Iran

⁴General physician, Mazandaran University of Medical Sciences, Sari, Iran

⁵Department of General Surgery, Mazandaran University of Medical Sciences, Sari, Iran

Received: Sep 11, 2016, Revised: Oct 10, 2016, Accepted: Oct 22, 2016

Abstract

Acute venous congestion leads to blood stasis in the tissue and impaired blood perfusion. Using medicinal leech is an old method for reducing tissue congestion. There are numerous factors in leech saliva and hirudin that have important roles in the leeching beneficial effect. In this study, an animal study was performed to compare leech therapy with heparin therapy in the treatment of acute venous congestion. Thirty male rats were divided into three groups. In the first group, an acute venous congestion was induced at the thigh. Decongestion was performed through the touch of *hirudo medicinalis* leech. In the second group, heparin sodium was injected, after tourniquet removal. Eventually, no treatment or procedure was performed in the third group after opening of tourniquet. Histopathological and biochemical analysis were performed in these rat. Edema size in heparin therapy and control groups was significantly greater than leech therapy group. Creatine phosphokinase blood level in leech therapy group was significantly lower than the control group, but this difference was unobserved between heparin therapy and control. In contrast, the level of lactate dehydrogenase and aldolase greatly increased in the control group, which received no intervention. Also in histopathological assessment, the level of tissue damage in both heparin and leech therapy groups showed a significant decrease as compared to the control group. Leech therapy can probably be more effective in the reducing of cellular damage caused by acute tissue congestion as compare to heparin therapy.

Keywords: Leech, heparin, vein, congestion

Pharm Biomed Res 2016; 2(3): 25-30

DOI: 10.18869/acadpub.pbr.2.3.25

Introduction

Surgical intervention is associated with venous manipulations that may cause the risk of acute venous congestion. Venous congestion is caused by an imbalance between arterial input and venous output blood flow. This leads to blood stasis in the tissue and impaired tissue perfusion, hypoxia, acidosis, arterial thrombosis, and eventually, tissue necrosis and gangrene (1,2). Using medicinal leech is an old method for reducing of tissue congestion, which it is interesting tool for improvement of venous congestion. Leeching improves blood flow through venous decongestion, especially in reconstructive surgeries. Leeches absorb blood through proboscis, and there are numerous anticoagulant factors in leech saliva. Among more than 100 bioactive substances, hirudin plays the

most important role through interfering with blood clotting process. Hirudin blocks the activity of thrombin, and stops the conversion of fibrinogen to fibrin. Today hirudotherapy is used in reconstructive surgery to remove the collection of blood under the skin flap, particularly in microvascular free flaps (3,4,5). Several studies have shown that the most frequently cited reason for failure of microvascular free flaps is the compromise of venous outflow (5). Other procedures have been suggested such as injection of heparin along with bloodletting via stab incisions (6), hyperbaric oxygen therapy (7), and the use of the medicinal leech (8). Avci *et al.* and Heckmann *et al.* used leeches for treating of patients who suffered from a hematoma and neurovascular compression.

They showed that the use of leeches reduced significantly tissue congestion (9, 10). In other studies by Grossman *et al.* and Lee *et al.*, they found that leeches can be used in the treatment of tongue hematoma emerged after trauma (11, 12). Chepeha *et al.* showed the use of leeches in vascular obstruction of eight patients, after head and neck free tissue transfer surgeries. They showed this protocol can salvage free tissue transfers with venous obstruction that are otherwise unsalvageable (13).

Since an experimental study has not been conducted to compare leech therapy with the existing conventional method, this animal was performed to compare leech therapy with heparin therapy in the treatment of acute venous congestion.

Material and methods

In this study, 30 male Wistar rats, weighing 300 ± 30 grams were prepared from animal house of Mazandaran University of Medical Sciences Rats were maintained on a 12 hour light/dark cycle at 24 ± 1 °C and $60 \pm 10\%$ humidity. The animals were kept in standard room conditions and fed with standard rat diet and water. All the animals were healthy and at the same age. First, the rats were randomly divided into three groups of 10 members. Then, general anesthesia was undertaken through Intraperitoneal injection of ketamine hydrochloride 10% (Rotexmedica, Trittau, Germany), at a dosage of 60 mg/kg.

Leg circumference was measured before and after the experiment at the middle part of the congested thigh using a non extensible scaled tapeline in mm. In the first group, the right lower limb` hairs were shaved, and then an acute venous congestion was made at the top of the thigh, using a rubber band. The rubber band closed forcefully to obstruct vascular circulation of limb. Tourniquet removed after three hours; then, we tried to do decongestion, through the touch of a 5-7 cm *Hirudo medicinalis* leech (from Pasteur Institute, Tehran, Iran) to the right thigh. All the animals had 10 minutes of sucking. After 10 minutes, if the leech didn't stop sucking, we removed it by stimulating the jaws. In the second group, 120 units of heparin sodium (from Caspian Tamin Pharmaceutical Co. Rasht, Iran) were injected under abdomen skin, after tourniquet removal, and then the dose was repeated 12 hours later. Eventually, no action was done in the third group after tourniquet removal. After 24 hours, the animals were euthanized (200 mg/kg of pentobarbital sodium, interaperitoneal) in a painless way. The level of lower extremity edema was measured by the middle part of the thigh circumference. Then, the muscle samples were collected from the right hind limb. A pathologist who was blinded to sample origin examined the collected tissues. Histopathological analysis and measurement of the severity of congestion, inflammation and thrombosis were performed (Table 1). Finally, 5 mL of blood were collected directly from the animal's heart and lactate dehydrogenase (LDH),

Table 1 Pathological assessment and grading of tissue damage

Parameter	Score
Presence of vascular congestion (stasis) in surrounding connective tissue	None (0), mild (+), moderate (++), marked (+++)
Presence of extravasated RBC's in the muscular tissue	None (0), mild (+), moderate (++), marked (+++)
Presence of edema	None (0), mild (+), moderate (++), marked (+++)
Blood vessels thrombi	Absent, present
Presence of inflammation	None (0), mild (+), moderate (++), marked (+++)
Tissue necrosis	Absent, focally present, extensively present
Vascular damage (swelling, necrosis, inflammation)	Absent, present

Aldolase, creatine phosphokinase (CPK), sodium, potassium, calcium, and phosphor were determined. Measurement of LDH, CPK, calcium and phosphor was done through photometric method (kit from Pars Azmoon Co., Tehran, Iran) using autoanalyzer (BT-3000 PLUS, DGKC, Italy), and of sodium and potassium using electrolyte analyzer (Starlyte TM 5, China).

Ethical consideration

All experimental interventions and animal care were performed in accordance with the local animal care committee of Mazandaran University of Medical Sciences (research ethical code 93-4-18).

Statistical analysis

Data entry and analysis were done using SPSS version 16 (USA), using ANOVA, Post hoc chi square and Tukey statistical tests. In all cases, a p value less than 0.05 was considered as statistically significant.

Results

Macroscopic assessment

Edema size at the end of treatment in heparin therapy and control groups were significantly greater than leech therapy group ($p = 0.001$). There was no noticeable effect of heparin therapy before and after the experiment in edema size in comparison to control group.

Biochemical assessment

Intracellular ions, such as phosphor and potassium, as well as extracellular ions, like sodium and calcium, were no significantly different in the three groups. On the other hand, CPK blood level in leech therapy group was significantly lower than the control group ($p = 0.015$), but this difference was unobserved between heparin therapy and control groups ($p = 0.015$). In contrast, levels of LDH and aldolase in both leech therapy ($p = 0.01$) and heparin therapy groups showed the lowest increase than the control ($p = 0.0001$). In other words, the level of these two enzymes greatly increased in tissue ischemic conditions in the control group, which received no intervention (Table 2).

Histopathological assessment

In histopathological analysis of soft tissue of lower limb, all three groups showed some degree of damage. However, no significant difference in thrombus formation, vascular congestion (stasis) in surrounding connective tissue, and tissue necrosis was observed. Moreover, the vascular damage, which is defined in the form of inflammation, necrosis and swelling, was the most in the control group comparing other two ones ($p = 0.014$) (Fig. 1). Presence of extravasated RBC's in the muscular tissue was also the most in the control group, which did not receive any intervention, compared to heparin and leech therapy groups ($p = 0.003$).

Table 2 Comparison of the biochemical findings in animals with heparin and leech therapy

Parameter	Leech therapy (mean ± SD)	Heparin therapy (mean ± SD)	Control (mean ± SD)	p value*
CPK (u/l)	1629 ± 981	2924 ± 2070	4584 ± 3054	0.02
LDH (u/l)	3585 ± 997	4094 ± 972	5899 ± 1704	0.001
Aldolase (u/l)	17.41 ± 13.2	1.85 ± 1	117.8 ± 45.1	<0.001
Phosphorus (meq/l)	10.4 ± 2.9	9 ± 1.7	11.5 ± 2.3	0.08
Sodium (meq/l)	146.6 ± 3.3	147.6 ± 2.6	145.3 ± 2.8	0.24
Potassium (meq/l)	7.27 ± 0.5	7.34 ± 0.27	7.26 ± 0.32	0.88

* Statistical differences between three groups or intergroup

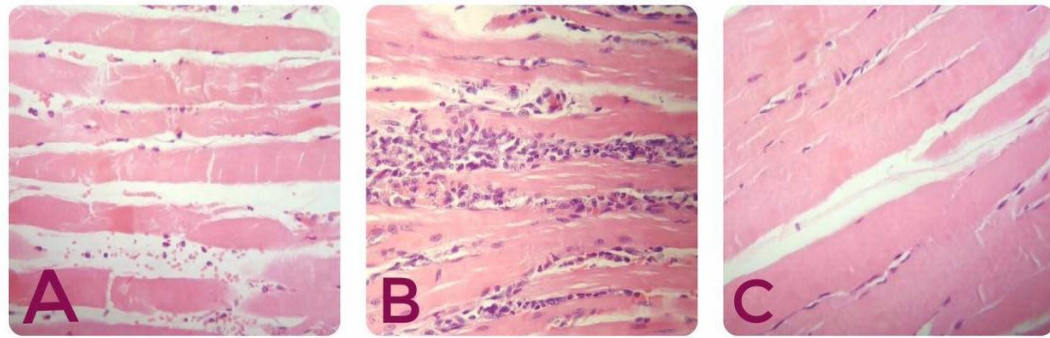


Figure 1 Leech treated group (C) show less inflammation compared to heparin (A) treated and no medicated (B) groups. (H & E stained slides, x100 magnified respectively by light microscopy).

Besides, tissue inflammation was at the lower rate in both heparin ($p = 0.02$) and leech therapy groups (0.012), based on the presence of inflammatory cells and also tissue edema. In general, the level of tissue damage in both heparin and leech therapy groups showed a significant decrease, compared to the control group (Table 3).

Discussion

Leeching is considered by many to be a discredited medical relic of the past. This view is not justified, since leeches still play an important part in modern medicine, as in microsurgery and in the treatment of patients with post-phlebotic syndrome (14). The leech bite produces a small bleeding wound that serves as an alternative source of venous outflow, which allows the leech to maintain nutritive capillary perfusion to compromised tissue. Furthermore, the leech could improve the capillary blood flow by inserting anticoagulant substances and vessel dilator agents, and removing an amount of blood out of the tissue through suction. Leech saliva contains numerous anticoagulant factors, such as Hirudin, factor Xa inhibitor, a platelet aggregation inhibitor (apyrase), Calin, hirustatin, bdellins and eglins destabilase, which facilitate infiltration of antithrombotic agents into the congested tissue (1). Therefore, the effectiveness of medicinal leech therapy in relieving venous congestion is due to both mechanical and biological effects.

One of the most well-known factors available in the saliva of leeches is a polypeptide called

Hirudin, which acts as an anticoagulant through directly inhibiting thrombin. It doesn't need antithrombin 3 to act, and can block the final stage of both internal and external pathways. In contrast, heparin needs antithrombin 3 to inactivate thrombin (15). Therefore, in cases where we have a person deficient in antithrombin 3, Hirudotherapy would be a useful option. Similarly, in patients who are at the risk of heparin-induced thrombocytopenia, leech therapy is an appropriate choice (16). Animal studies have shown that lactic acid and creatine phosphokinase increase using the tourniquet 2 hours after ischemia, which indicates a muscle damage (17). In a case series and meta-analysis, de Chalain reviewed 108 cases in which leeches were applied to replants, free-tissue transfers, and pedicle flaps for an average of 4.2 days for venous congestion. The survival rate was 83% in 89 uninfected cases (18). In a similar study Baudet concluded that the use of leeches in distal digital replantation improve the survival rate by 26% (19). No comparison was made in these studies among the current common treatments with leech therapy. In another study by Chepeha *et al.* 8 cases out of 450 free tissue transfers in head and neck were with tissue congestion, which weren't healed by conventional treatment. The improvement was observed in all cases by adding leech treatment. They concluded that the effect of leech therapy in relieve of venous

Table 3 Pathological findings in rat's limb ischemia managed by heparin and leech therapy

Group		Leeching	Heparin therapy	Control	<i>p</i> value *
Pathology		(N)	(N)	(N)	
Vascular damage	Yes	3	0	6	0.014
	No	7	10	4	
Extravasation	None	5	6	0	0.003
	Mild	3	3	3	
	Moderate	1	1	3	
	severe	1	0	4	
Inflammation	None	1	0	0	0.020
	Mild	4	6	2	
	Moderate	5	4	3	
	marked	0	0	5	
Tissue edema	None	5	3	1	0.012
	Mild	3	7	2	
	Moderate	2	0	6	
	marked	0	0	1	

* Statistical differences between three groups or intergroup

congestion is due to both mechanical and biological effects. Each leech directly extracts 5 to 15 mL of blood from the flap, but an extra 20 to 50 mL of blood is lost from oozing from the bite site after the leech detaches (13, 20). No comparison with control group was done in this study. It has been shown that heparin decreases mortality and morbidity in acute limb ischemia, through preventing of thrombus expansion. In thrombogenesis period, when fibrinogen converts to fibrin, thrombin is banded to fibrin. This connection expands thrombosis. Unlike heparin, hirudin both releases thrombin and disables clot-bound Thrombin. So it could prevent thrombus expansion even after fading out of circulation.

The reason of the expansion of thrombus in patients with venous thromboembolism is the accretion of fibrin with the existing Thrombin. Heparin is an effective antithrombotic agent, when is continuously prescribed. Heparin is highly effective in inhibiting fluid phase thrombin, but is a relatively ineffective inhibitor

of thrombus-bound thrombin. Hirudin, unlike heparin, inactivates both circulating and fibrin-bound thrombin. So, has the potential to prevent thrombus extension even after a short course of treatment (21). In this study, three groups of rats were examined. As it was shown, leech therapy, like heparin therapy, can decrease vascular damages, tissue inflammation, tissue edema and vascular extravasations, comparing to the control group. Elevation of CPK, LDH and aldolase are indicators of muscle injury. As we know, when a muscle is damaged, these enzymes leak into the bloodstream. It seems a little increase of these enzymes in the experimental groups indicates their favorable impact on the tissue decongestion, and cell damage prevention. Interestingly, the increase in CPK, as a key indicator of muscle cell damage, was little in leech therapy group compared to the control group. But, the difference was not significant in heparin therapy group. It may be concluded this way that leech

therapy is more successful in reducing cellular damage caused by acute tissue congestion, compare to heparin therapy. Also, limb edema was lower in the leech therapy group compared to the control group, which perhaps is due to the removal of blood by the leech. However, this mechanism can also be effective in reducing tissue damage.

Conclusion

Leech therapy can probably be more effective in reducing cellular damage caused by acute tissue

congestion, compare to heparin therapy. Although hirudin is available in the market, but the use of leeches is much cheaper. So, with regard to the simplicity, fast effects and cost-effectiveness of the leech therapy, we suggest the medical staff to consider this method in their medications too, though it needs further studies in human series.

Conflict of interest

All authors declare that they have no conflict of interest with respect to authorship, and/or publication of this study.

References

1. Singh AP. Medicinal leech therapy (hirudotherapy): a brief overview. *Complement Ther Clin Pract* 2010; 16:213-5.
2. Porshinsky BS, Saha S, Grossman MD, Beery LP, Stawicki S. Clinical uses of the medicinal leech: A practical review. *J Postgrad Med* 2011; 57:65-71.
3. Gröbe A, Michalsen A, Hanken H, Schmelzle R, Heiland M, Blessmann M. Leech therapy in reconstructive maxillofacial surgery. *J Oral Maxillofac Surg* 2012; 70:221-7.
4. Goessel C, Steffen-Wilke K, Miller K. Leech therapy for massive scrotal hematoma following percutaneous transluminal angioplasty. *J Urol* 1997; 158:545.
5. Koch CA, Olsen SM, Moore EJ. Use of the medicinal leech for salvage of venous congested microvascular free flaps of the head and neck. *Am J Otolaryngol* 2012; 33:26-30.
6. Robinson C. Artificial leech technique. *Plast Reconstr Surg* 1998; 102:1787-8.
7. Gampper TJ, Zhang F, Mofakhami NF, Morgan RF, Amiss R, Hoard MA, et al. Beneficial effect of hyperbaric oxygen on island flaps subjected to secondary venous ischemia. *Microsurgery* 2002; 22:49-52.
8. Hullett JS, Spinnato GG, Ziccardi V. Treatment of an ear laceration with adjunctive leech therapy: a case report. *J Oral Maxillofac Surg* 2007; 65:2112-4.
9. Avci G, Akan M, Yildirim S, Aköz T. Digital neurovascular compression due to a forgotten tourniquet. *Hand Surg* 2003; 8:133-6.
10. Heckmann JG, Dütsch M, Neundörfer B, Dütsch F, Hartung U. Leech therapy in the treatment of median nerve compression due to forearm haematoma. *J Neurol Neurosurg Psychiatry* 2005; 76:1465.
11. Grossman MD, Karlovitz A. Lingual trauma: the use of medicinal leeches in the treatment of massive lingual hematoma. *J Trauma* 1998;44:1083-5.
12. Lee NJ, Peckitt NS. Treatment of a sublingual hematoma with medicinal leeches: report of case. *J Oral Maxillofac Surg* 1996;54:101-3.
13. Chepeha DB, Nussenbaum B, Bradford CR, Teknos TN. Leech therapy for patients with surgically unsalvageable venous obstruction after revascularized free tissue transfer. *Arch Otolaryngol Head Neck Surg* 2002; 128:960-5.
14. Eldor A, Orevi M, Rigbi M. The role of the leech in medical therapeutics. *Blood Rev* 1996; 10:201-9.
15. Green PA, Shafritz AB. Medicinal leech use in microsurgery. *J Hand Surg Am* 2010; 35:1019-21.
16. Markwardt F. Hirudin as an alternative anticoagulant: a historical review. *Semin Thromb Hemost* 2002; 28:405-13.
17. Tran TP, Tu H, Pipinos II, Muellemann RL, Albadawi H, Li YL. Tourniquet-induced acute ischemia-reperfusion injury in mouse skeletal muscles: Involvement of superoxide. *Eur J Pharmacol* 2011; 10: 328-34.
18. De Chalain TMB. Exploring the use of the medicinal leech: a clinical risk-benefit analysis. *J Reconstr Microsurg* 1996; 12:165-72.
19. Baudet J. The use of leeches in distal digital replantation. *Blood Coagul Fibrinolysis* 1991; 2:193-6.
20. Derganc M, Zdravic F. Venous congestion of flaps treated by application of leeches. *Br J Plast Surg* 1960; 13:187-92.
21. Agnelli G, Renga C, Weitz JI, Nenci GG, Hirsh J. Sustained antithrombotic activity of hirudin after its plasma clearance: comparison with heparin. *Blood* 1992;80: 960-5.